

Institutional report - Cardiopulmonary bypass

First experience with the ultra compact mobile extracorporeal membrane oxygenation system Cardiohelp in interhospital transport

Alois Philipp^a, Matthias Arlt^b, Matthias Amann^b, Dirk Lunz^b, Thomas Müller^c, Michael Hilker^a, Bernhard Graf^b, Christof Schmid^{a,*}

^aDepartment of Cardiothoracic Surgery, University Medical Center, Franz-Josef-Strauss-Allee 11, 93053 Regensburg, Germany

^bDepartment of Anesthesiology, University Medical Center, Regensburg, Germany

^cDepartment of Internal Medicine II – Pneumology, University Medical Center, Regensburg, Germany

Received 23 December 2010; received in revised form 10 February 2011; accepted 14 February 2011

Abstract

In patients with severe cardiopulmonary failure extracorporeal assist devices are to support patients during resuscitation, for transportation, until organ recovery, and as bridge to further therapeutic modalities. We report on our first experience with the new Cardiohelp system for interhospital transfer of cardiopulmonarily compromised patients. The Cardiohelp system was used for transportation and in-house treatment in six male patients with a mean age of 41 ± 17 years. Five patients suffered respiratory failure; one patient with acute myocardial infarction was in profound cardiogenic shock. Accordingly, the Cardiohelp system was implanted as a venovenous extracorporeal membrane oxygenation (ECMO) in five patients and as a venoarterial system in one patient. The preECMO ventilation time was 0.5–4 days. The patients were transported to our institution by car ($n=1$) or helicopter ($n=5$) over a distance of 80–5850 km. The subsequent in-house ECMO support was continued with the Cardiohelp and lasted for 5–13 days. PostECMO ventilation was one to 25 days. A 100% survival was achieved. The portable Cardiohelp system allows location-independent stabilization of cardiopulmonary compromised patients with consecutive interhospital transfer and in-house treatment. The integrated sensors, which register arterial and venous line pressure, blood temperature, hemoglobin as well as SvO_2 , greatly alleviate its management and considerably increase safety. © 2011 Published by European Association for Cardio-Thoracic Surgery. All rights reserved.

Keywords: Cardiohelp; Extracorporeal life support; Extracorporeal membrane oxygenation; Interhospital transfer; Patient transport

1. Introduction

Patients with severe cardiopulmonary failure have a dismal prognosis despite numerous advances in emergency and intensive care medicine. Extracorporeal life support (ECLS) and extracorporeal membrane oxygenation (ECMO) are interchangeable terms for what has become a therapeutic option in acute cardiac pump failure or pulmonary hypoxic/hypercapnic failure. These devices are highly effective; however, their use is restricted to specialized centers as primary care institutions cannot provide all the necessary technical and personal resources. Therefore, patients with severe pulmonary failure have to be referred to a center with expertise in extracorporeal lung support, and patients with cardiogenic shock have to be taken to institutions offering appropriate mechanical long-term support and heart transplantation [1, 2]. The out-of-center implantation of extracorporeal support devices and consecutive transport of patients to an ECMO institution is a logistic challenge with a high potential for complications. We report on our first experience with the new portable

Cardiohelp system for interhospital transfer of cardiopulmonarily compromised patients.

2. Patients and methods

2.1. Patient cohort

From March 2006 to October 2010, 74 adult patients were provided with an extracorporeal support system in a distant city hospital, and were transferred to our institution thereafter [3]. Since July 2010, the new compact Cardiohelp system was used in six patients to assess its handling and reliability for patient transportation. All patients were severely compromised with regard to cardiac, pulmonary or cardiopulmonary function, and were under maximal conservative therapy. Three patients had undergone cardiopulmonary resuscitation.

2.2. The Cardiohelp system

The Cardiohelp system (Maquet Cardiopulmonary AG, Hirrlingen, Germany) is a lightweight (10 kg), ultra compact, and portable extracorporeal perfusion system with a power supply of two hours. First time ever, a membrane oxygenator, a centrifugal pump, arterial and venous pres-

*Corresponding author. Tel.: +49-941-944-9801; fax: +49-941-944-9802.

E-mail address: christof.schmid@klinik.uni-regensburg.de (C. Schmid).

sure sensors, temperature monitoring, as well as measuring devices for mixed venous saturation and hemoglobin are put together to create a single exchangeable component. Measured data are stored and can be analyzed later. As all blood contact surfaces of the system are heparin coated with the Bioline technique (Maquet Cardiopulmonary AG, Hirrlingen, Germany), systemic anticoagulation can be kept at a minimum.

The Cardiohelp system has European certificate for 30 days use and allows, apart from in-hospital use, also interhospital transfer with ground or air ambulance vehicles (Figs. 1 and 2).

2.3. Transport team and logistics

As the transport of critically ill patients is an interdisciplinary task, the team consisted of a cardiac anesthesiologist, a cardiac surgeon, and a pump technician. All were available 24/7 [4, 5]. During working hours, activation of the team required <10 min, afterhours up to 60 min were necessary. All indispensable tools were pre-packed in a box. The Cardiohelp system was primed with crystalloid fluids prior to departure in order to be ready to use immediately upon arrival. No time is lost and device placement can be rapidly initiated. For the consecutive patient transportation, an intensive care transport van and a rescue helicopter (Eurocopter EC) were available.

2.4. Patient management and transportation

The transport request was initialized by a phone call. Patient suitability was assumed and confirmed following a check list evaluation during the interhospital phone contact. With acceptance of the patient, the preparation of 2 U of red blood cells and sonographic measurement of the femoral vessel diameter was asked for.

Upon arrival of the transport team, the patient was carefully assessed, the indication was reaffirmed, and it was determined which mode of mechanical support (venoarterial, venovenous, cannulation sites) was most suitable for the patient. After vessel puncture, a guide wire was placed percutaneously, and 5000 U of heparin were medicated [6]. The vascular access was enlarged with several dilators passed over the wire until the respective cannula

could be safely placed. In all patients, a 23-French cannula (BE-PVS 2338, Maquet CP, Hirrlingen, Germany) was used for drainage in the right femoral vein. The arterial return was achieved with a 17-French cannula via the jugular vein in venovenous ECMOs, and via the left femoral artery in venoarterial ECMOs. All cannulas were fixed with Hollister systems (Hollister, Libertyville, IL, USA) to prevent displacement.

After connection of the Cardiohelp system, a brief stabilization period to improve hemodynamics and blood gases followed prior to patient transportation. For transport, the patients were placed onto a standard stretcher (Stryker) (Fig. 2). Patient monitoring had the same level as for a normal ICU transport, with special attention being focused on the continuous oxymetry. During transportation, power supply and necessary gas flow for the oxygenator were both provided by the transport vehicle.

3. Results

3.1. Cases

Patient no. 1: A 38-year-old male suffered acute ST elevation myocardial infarct with cardiogenic shock. Cardiac catheterization revealed occlusion of the R. interventricularis anterior (RIVA). An intraaortic balloon pump was inserted following an episode of ventricular fibrillation. The patient was provided with a venoarterial ECMO and cooled for neuroprotection for 24 h [7]. After nine days, a paracorporeal left-ventricular assist device (Excor, Berlin Heart, Berlin) was implanted. Currently, the patient is at home and awaiting heart transplantation.

Patient no. 2: A 38-year-old male with high grade aortic valve stenosis and cardiogenic as well as septic shock (body temperature >40 °C) with bilateral pneumonia and lung edema. External chest massage became necessary prior to intubation. A venovenous ECMO was implemented to allow lung protective ventilation, since hypoxia was the assumed primary problem. Three weeks later, a successful aortic valve replacement was performed.

Patient no. 3: A 24-year-old patient had a car accident being not buckled up with his seat belt. The patient was catapulted out of his car and experienced traumatic head



Fig. 1. Helicopter transport with the Cardiohelp system.

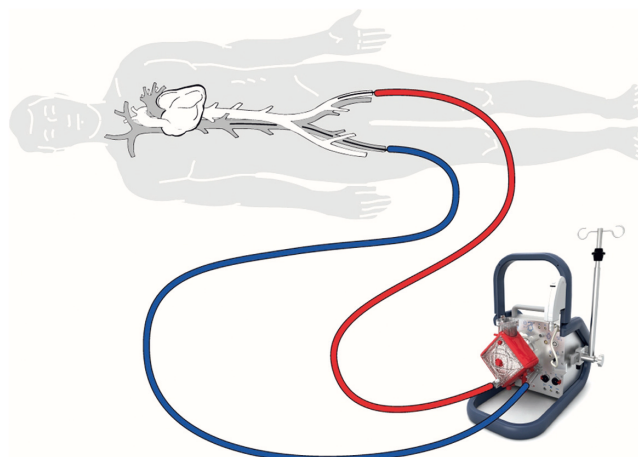


Fig. 2. Cardiohelp circuit.

and brain injuries and multiple bone fractures. On day 3, he developed an acute respiratory distress syndrome (ARDS). He was placed on a venovenous ECMO system for 11 days and fully recovered.

Patient no. 4: A 22-year-old soldier with thoracic gunshot injury and subsequent right-sided pneumonectomy and partial left-sided lung resection went into critical respiratory failure. A venovenous ECMO was connected in the war region and the patient referred to a military hospital by plane, and then to us by helicopter over a total distance of 5850 km. Thirteen days on ECMO allowed sufficient recovery of pulmonary function. One day after ECMO termination, he was extubated and then referred to a US military hospital.

Patient no. 5: A 63-year-old patient with pneumonia due to legionella infection developed sepsis, ARDS, and multi-organ failure. He was treated with venovenous ECMO support for seven days but needed additional high frequency oscillatory ventilation (HFOV) to prevent hypoxemia. Thereafter, he recovered rapidly.

Patient no. 6: A 59-year-old patient suffered severe sepsis and ARDS following pseudomonas infection. Despite HFOV, oxygenation was insufficient and right heart failure was evident. The patient was connected to venovenous ECMO to relieve hypoxia in a deleterious situation with 50 mg/h epinephrine. After 13 days of mechanical support weaning was successful and the patient's condition improved.

All six patients were male; the mean age was 41 ± 17 years. All cases were in a life-threatening situation. Five patients suffered respiratory failure; one patient with acute myocardial infarction went into cardiogenic shock. Accordingly, the Cardiohelp system was implanted as a venovenous ECMO in five patients and as a venoarterial system in one patient. The preECMO ventilation time was 0.5–4 days (Table 1).

With initiation of the extracorporeal support, hemodynamics improved immediately and the gas exchange situation stabilized within minutes in all patients. The patients were transported to our institution by car ($n=1$) or helicopter

($n=5$) over a distance from 80 to 5850 km. The transport was uneventful except for a temporary systemic pressure drop. In our institution, the ECMO support with the Cardiohelp was continued for 5–13 days. For venovenous ECMO, the average support interval was 9.8 ± 3.6 days, whereas the single patient with a venoarterial ECMO underwent LVAD placement after recuperation from multi-organ failure on day 9. Cannulation was always percutaneously, employing Seldinger's technique. After weaning from ECMO, further ventilation was necessary for 1–25 days. All patients being transported by ground or air ambulance survived and could be finally discharged home. Five patients were neurologically asymptomatic, patient no. 5 recovered from a right-sided stroke related to severe atherosclerosis (Table 2).

3.2. Complications

No complications related to the ECMO system occurred during device implantation and during patient transport. In patient no. 4, the ECMO system had to be exchanged for an oxygenator thrombosis at day 4. Following a redo thoracotomy for bleeding, its flow resistance increased from 25 mmHg to 160 mmHg at 3.0 l/min [8]. At that time, 1000 IU/h of heparin were continuously administered. Partial thromboplastin time was 50 s, which was the target level [9]. After the exchange of the ECMO system, the resistance dropped to 20 mmHg. During visual inspection, the oxygenator showed massive thrombotic apposition.

4. Discussion

This is a report on the first use of the portable Cardiohelp ECMO system for ground- and air-based interhospital transport. Transportation of patients with extracorporeal circulatory support is not new. John B. Bennet and colleagues from Portland, Oregon, already described an interhospital transport of patients with venoarterial ECMO in 1994 [10]. However, the portable heart–lung machine was extremely bulky and heavy, and cannulas were mainly inserted surgically. A small and mobile ECMO system with a weight of 25 kg was introduced by Vlad Gaiboldi, but it did not have an integrated monitoring [11]. In our institution, a portable miniaturized ECMO system with an excellent handling weighing <20 kg was developed and used until summer 2010. In that system, monitoring was considerably restricted too, i.e. it was not possible to measure arterial or venous line pressure [12–14].

With the Cardiohelp system a highly sophisticated miniaturized heart–lung machine became available. Our initial

Table 1. Patient data

	<i>n</i>
Number of patients	6
Type of ECMO	
Venovenous	5
Venoarterial	1
Indication for ECMO	
Respiratory failure	5
Cardiac failure	1
Age/gender	
Male	6
BMI (kg/m ²)	1.86–2.50
Days in hospital before ECMO (days)	0.5–4.0
Ventilation before ECMO (days)	0.5–4.0
Resuscitation before ECMO	3
Sofa score	12–16
Lung injury score	2.3–3.9
paO ₂ /FiO ₂ ratio (mmHg)	42–65
paCO ₂ (mmHg)	35–90
Serum lactate (mg/dl)	31–163
Mean arterial blood pressure (mmHg)	51–71
Norepinephrine (μg/kg/min)	0.4–7.5

ECMO, extracorporeal membrane oxygenation.

Table 2. Transport data

	<i>n</i>
Mode of transport	
Helicopter	5
Ambulance care	1
On scene time (min)	90–180
Transport distance (km)	80–5850
Days on ECMO	5–13
Days on ventilator postECMO	1–25

ECMO, extracorporeal membrane oxygenation.

tests using the Cardiohelp as miniECC for coronary artery bypass grafting proved its excellent function and demonstrated great reliability. Then, the system was introduced to our dedicated interdisciplinary patient transport team to be used as venoarterial or venovenous ECMO, i.e. to replace the older portable MECC system from Maquet. All ECMO patient transports with the Cardiohelp system were successful, no significant complication occurred. The handling of the system was excellent, inside the helicopter and in the ambulance car. The online pressure monitoring of the venous line proved to be quite advantageous to judge the patient's volume status. Progressive negative pressure levels, despite a constant pump flow, indicates a volume deficit, which can be easily treated. The second important measurable parameter was the mixed venous saturation (SvO₂), which was continuously assessed in the venous line [15]. An increase of the SvO₂ points towards a hemodynamic stabilization of the patient, whereas a decrease of the SvO₂ is an early sign for hemodynamic instability. Recirculation problems in a venovenous ECMO could also be recognized immediately, and counteracted by repositioning of the cannulas.

A long distance transport did not seem to raise considerable obstacles. The patient has to be well prepared and stable on ECMO prior to the start. During transport, the power cord of the Cardiohelp system has to be connected to the vehicle's system to spare the internal batteries. The oxygen for the gas exchange is handled in a similar way, i.e. is taken from the transport vehicles' oxygen supply. Thus, an almost unlimited mileage is possible. Being well aware of this option, several military institutions are currently implementing the Cardiohelp system to bring their wounded soldiers home from war, as has been done in patient no. 4.

After a successful transport to a tertiary care facility, the patient can remain on the Cardiohelp for further long-term mechanical support. An exchange of the system to a standard ECMO is not necessary. Only if the Cardiohelp fails for thrombus deposition or other reasons, one may employ a standard ECMO if its costs were lower. In case of acute myocardial infarction, the patient can undergo a coronary revascularization while on support by the Cardiohelp, and can even be left connected thereafter.

The portable Cardiohelp system allows location-independent stabilization of cardiopulmonary compromised patients with consecutive interhospital transfer and further in-house treatment. The integrated sensors, which register line

pressure, blood temperature, hemoglobin as well as SvO₂, greatly alleviate its management and considerably increase safety.

References

- [1] Bartlett R, Gattinoni L. Current status of extracorporeal life support (ECMO) for cardiopulmonary failure. *Minerva Anestesiol* 2010;76:534–540.
- [2] Schmid C, Philipp A, Hilker M. Extracorporeal life support systems. Indications and limitations. *Thoracic Cardiovasc Surg* 2009;57:449–454.
- [3] Haneya A, Philipp A, Foltan M, Mueller T, Camboni D, Rupprecht L, Puehler T, Hirt S, Hilker M, Kobuch R, Schmid C, Arlt M. Extracorporeal circulatory systems in the interhospital transfer of critically ill patients: experience of a single institution. *Ann Saudi Med* 2009;29:110–114.
- [4] Feindt P, Benk C, Boeken U, Bauer A, Mehlhorn U, Gehron J, Markewitz A, Beckmann A, Beyersdorf F. Einsatz einer extrakorporalen Zirkulation (EKZ) außerhalb eines herzchirurgischen Operationssaals – Indikationen, Rahmenbedingungen und Empfehlungen für den praktischen Einsatz. *Kardiotechnik* 2010;3:58–60.
- [5] Dorlac G, Fang R, Pruitt V, Marco P, Stewart H, Barnes S, Dorlac W. Air transport of patients with severe lung injury: development and utilization of the acute lung rescue team. *J Trauma* 2009;66(Suppl 4):164–171.
- [6] Arlt M, Philipp A, Voelkel S, Rupprecht L, Mueller T, Hilker M, Graf BM, Schmid C. Extracorporeal membrane oxygenation in severe trauma patients with bleeding shock. *Resuscitation* 2010;81:804–809.
- [7] Nolan J, Soar J, Zidemann A, Biarent D, Bossaert L, Deakin C, Koster R, Wyllie J, Böttiger B. Kurzdarstellung – Sektion 1 der Leitlinien zur Reanimation 2010 des European Resuscitation Council. *Notfall Rettungs-med* 2010;13:515–522.
- [8] Lehle K, Philipp A, Gleich O, Holzamer A, Müller T, Bein T, Schmid C. Efficiency in extracorporeal membrane oxygenation – cellular deposits on poly-methylpentene membranes increase resistance to blood flow and reduce gas exchange efficiency. *ASAIO* 2008;54:612–617.
- [9] Bein T. Allgemeine Prinzipien der Intensivmedizin. Thieme Verlag Stuttgart 2009;2:105–113.
- [10] Bennet JB, Hill JG, Long WB 3rd, Bruhn PS, Haun MM, Parsons JA. Interhospital transport of the patient on extracorporeal cardiopulmonary support. *Ann Thorac Surg* 1994;57:107–111.
- [11] Gariboldi V, Grisoli D, Tarmiz A, Jaussaud N, Chalvignac V, Kerbaul F, Collart F. Mobile extracorporeal membrane oxygenation unit expands cardiac assist surgical programs. *Ann Thorac Surg* 2010;90:1552–1553.
- [12] Philipp A, Arlt M, Zimmermann M, Foltan M, Gietl M, Müller T, Bein T, Rupprecht L, Hilker M, Schmid C. Interhospitaltransfer mit Extrakorporalen Perfusionssystemen. *Kardiotechnik* 2008;1:8–13.
- [13] Arlt M, Philipp A, Voelkel S, Rupprecht L, Hilker M, Foltan M, Zimmermann M, Schmid C. A novel miniaturised extracorporeal circulation system for emergency percutaneous cardiopulmonary bypass in acute heart failure. *Heart Lung Circ* 2008;1:5.
- [14] Arlt M, Philipp A, Zimmermann M, Voelkel S, Hilker M, Hobbhahn J, Schmid C. First experiences with a new miniaturised life support system for mobile percutaneous cardiopulmonary bypass. *Resuscitation* 2008;77:345–350.
- [15] Rivers E, Ander D, Powell D. Central venous oxygen saturation monitoring in the critically ill patient. *Curr Opin Crit Care* 2001;7:204–211.